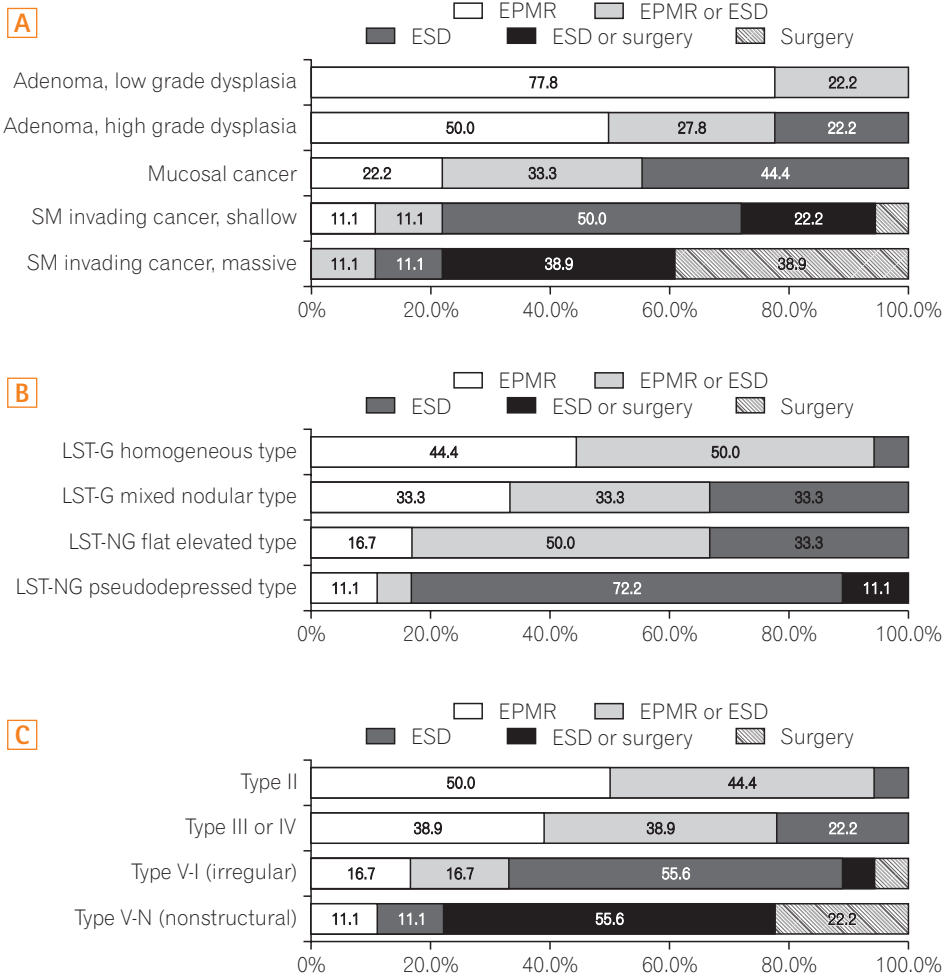
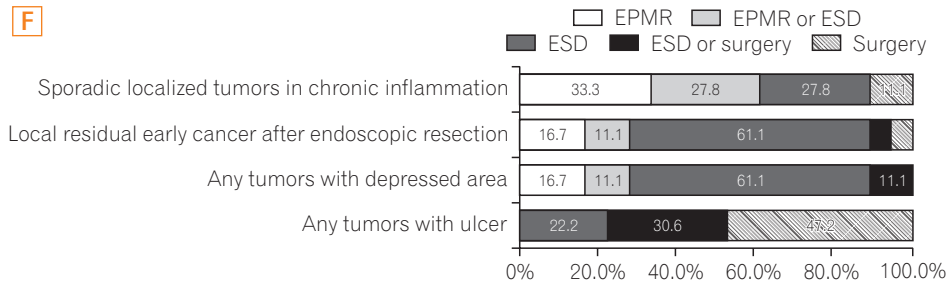
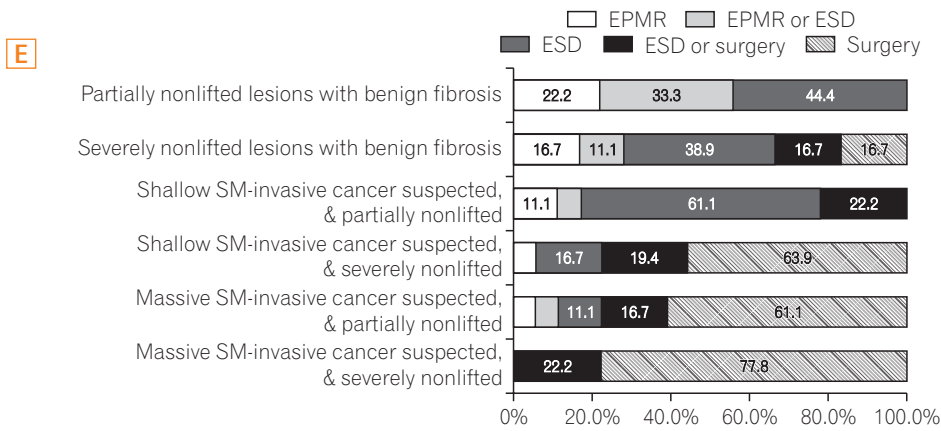
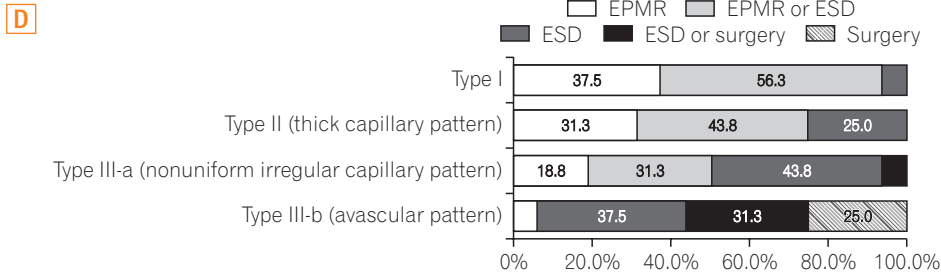


See "Current practices in endoscopic submucosal dissection for colorectal neoplasms: a survey of indications among Korean endoscopists" on page 228.



**Supplementary Fig. 1.** Endoscopists' approaches to treatment of tumor less than 2 cm in diameter: preprocedural assessment of (A) histology, (B) morphology, (C) pit pattern, (D) narrow band imaging pattern, (E) nonlifting sign, and (F) special situations. EPMR, endoscopic piecemeal mucosal resection; ESD, endoscopic submucosal dissection; LST-G, laterally spreading tumor granular; LST-NG, LST-nongranular; SM, submucosa.

See "Current practices in endoscopic submucosal dissection for colorectal neoplasms: a survey of indications among Korean endoscopists" on page 228.



Supplementary Fig. 1. Continued.